

Rapid maxillary expansion in growing patients. Hyrax versus transverse sagittal maxillary expander: a cephalometric investigation

Giampietro Farronato*, Cinzia Maspero*, Luca Esposito*, Enrico Briguglio*,
Davide Farronato** and Lucia Giannini*

Departments of *Orthodontics and **Surgery, Fondazione IRCCS Cà Granda - Ospedale Maggiore Policlinico, University of Milan, Italy

Correspondence to: Professor Giampietro Farronato, Department of Orthodontics, University of Milan, Via Commenda 10, 20122 Milano, Italy. E-mail: giampietro.farronato@unimi.it

SUMMARY The aim of this retrospective study was to cephalometrically evaluate and compare the skeletal and dental effects of a transverse sagittal maxillary expander (TSME) and a Hyrax-type expander (RME) in children with maxillary hypoplasia.

Fifty subjects (26 males and 24 females), aged from 6 to 15 years, with a maxillary crossbite caused by basal apical narrowness, were divided into two equal groups. Twenty-five were treated with a TSME and the other 25 with a RME. For each patient, a lateral cephalogram was obtained before treatment (T0) and at the end of the retention period (T1). Changes in the two groups during the observation period were calculated, compared, and statistically analysed with a paired samples *t*-test.

In the TSME group, SNP-A, ISN, and IFH and in the RME group SN-SNP.SNA, N-Me, and U6.PP displayed a statistically significant increase ($P < 0.05$). The increase in SNP-A, ISN, and IFH in the TSME group was significantly greater following treatment than in the RME group.

The results support the use of the TSME to produce skeletal changes and dentoalveolar modification and to correct maxillary hypoplasia. It was also demonstrated that in patients with an anterior open bite, the use of the TSME is not contraindicated as the anterior vertical dimension did not increase significantly.

Introduction

Rapid maxillary expansion is widely used in the treatment of transverse maxillary deficiencies in order to re-direct growth of the basal bone into a normal pattern.

Aetiological causes of a posterior crossbite can be either genetic or environmental. Harvold *et al.* (1972) stated that a reduction of the transverse maxillary dimension is generally due to anomalous functions.

A constricted arch width should be treated as early as possible to promote normal function and correct tongue positioning (Clark, 2005).

A low tongue position is associated with a narrow palate that may predispose to mouth breathing and also cause upper anterior crowding. Maxillary hypoplasia may cause a Class II malocclusion and may restrict mandibular development in the sagittal or transverse dimensions (McNamara and Brudon, 1993; Farronato *et al.*, 2003) and may also predispose to a Class III occlusion (Farronato *et al.*, 2003).

Early treatment protocols have been proposed to correct maxillary hypoplasia, and dentoalveolar and muscular imbalance before skeletal maturation and eruption of the permanent dentition is complete (McNamara and Brudon, 1993).

A rapid maxillary expander (RME) can produce orthopaedic expansion affecting the skeletal structures rather than movement of teeth through alveolar bone (Wertz, 1970; Timms, 1976).

Cephalometrically, it has been observed that the maxilla is displaced downward and forward during maxillary expansion (Haas, 1961; Wertz, 1970; Wertz and Dreskin, 1977; Linder-Aronson and Lindgren, 1979; Da Silva *et al.*, 1991). Cleall (1974) found unfavourable effects in patients with a well-positioned maxilla and stated that in the retention period the maxilla generally returns to its original position. Furthermore, in a study of lateral cephalograms, Wertz (1970) found that the maxilla consistently dropped down but rarely moved significantly forward. Wertz and Dreskin (1977) noted no significant change in the angulation of the palate after RME therapy.

In the retrospective studies of Farronato *et al.* (1982, 1983) on 15 growing subjects with maxillary hypoplasia, the effects of RME in the three planes of space were investigated. The cephalometric tracings were analysed before and after treatment and at the end of the retention period. The results of their study confirmed widening of the maxilla in the transverse plane and an increase in the floor of the nose.

In the sagittal plane, different effects were observed in Class I, II, and III subjects. In Class I patients, ANB angle was slightly affected while in all Class II subjects it decreased due to forwarding positioning of the mandible, confirming that orthopaedic force to the maxillary complex during the early phase of growth can contribute to the correction of Class II malocclusions. This phenomenon was described by McNamara and Brudon (1993) who stated that many Class II malocclusions have a strong transverse component and widening the maxilla disrupts the occlusion. They also observed that the patient becomes more comfortable by posturing the lower jaw slightly forward. The results are represented by resolution of the buccal crossbite and at the same time improvement in the sagittal occlusal relationship. Those authors suggested that the teeth themselves act as an endogenous functional appliance allowing a change both in mandibular posture and in the maxillomandibular occlusal relationship. This is the reason why in Class II malocclusion subjects with a reduced transpalatal width (less than 31 mm measured between the upper first molars) it was recommended to widen the maxilla using a RME.

Da Silva *et al.* (1991) did not observe any statistically significant maxillary modification in the sagittal position during RME treatment but a tendency to rotate downward and backward, increasing the SN–PP angle.

Akkaya *et al.* (1999) reported a significant increase in SNA, NPgA, SN/MP, ANB, ANS/PNS–MP angles during expansion. They also found a decrease in upper incisor/SN angle and overbite and an increase in overjet and E-plane measurements. They noted, in the post-treatment period, a decrease in SN–ANS/PNS, upper incisor/SN, and E-plane measurements and an increase in upper incisor/lower incisor angle and overbite.

Cozza *et al.* (2001), in a cephalometric investigation of 20 patients, noted that the maxilla displayed a tendency to rotate downward and backward, resulting in a statistically significant increase of SN/PP angle and SN–ANS linear values; results that are in agreement with the studies of Davis and Kronman (1969), Wertz (1970), Byrum (1971), Sarver and Johnston (1989), Da Silva *et al.* (1991), Asanza *et al.* (1997), and Akkaya *et al.* (1999).

Byrum (1971), Sarver and Johnston (1989), and Da Silva *et al.* (1991) found no statistically significant alteration in the antero-posterior position of the maxilla, which contradicts the conclusions of Davis and Kronman (1969) and Haas (1970).

Regarding the effects of RME treatment on the mandible, several authors have reported that opening of the midpalatal suture causes downward and backward rotation of the mandible and an increase in lower face height as a direct effect of vertical displacement of the maxilla (Haas, 1961, 1965, 1970; Davis and Kronman, 1969; Wertz, 1970; Wertz and Dreskin, 1977; Da Silva *et al.*, 1991; Akkaya *et al.*, 1999).

The aim of this retrospective study was to cephalometrically evaluate and compare the skeletal and dental effects of a new orthopaedic appliance (Farronato *et al.*, 2007), the transverse sagittal maxillary expander (TSME), for the correction of sagittal and transverse maxillary hypoplasia (Figure 1a) with the Hyrax-type RME in children with maxillary hypoplasia.

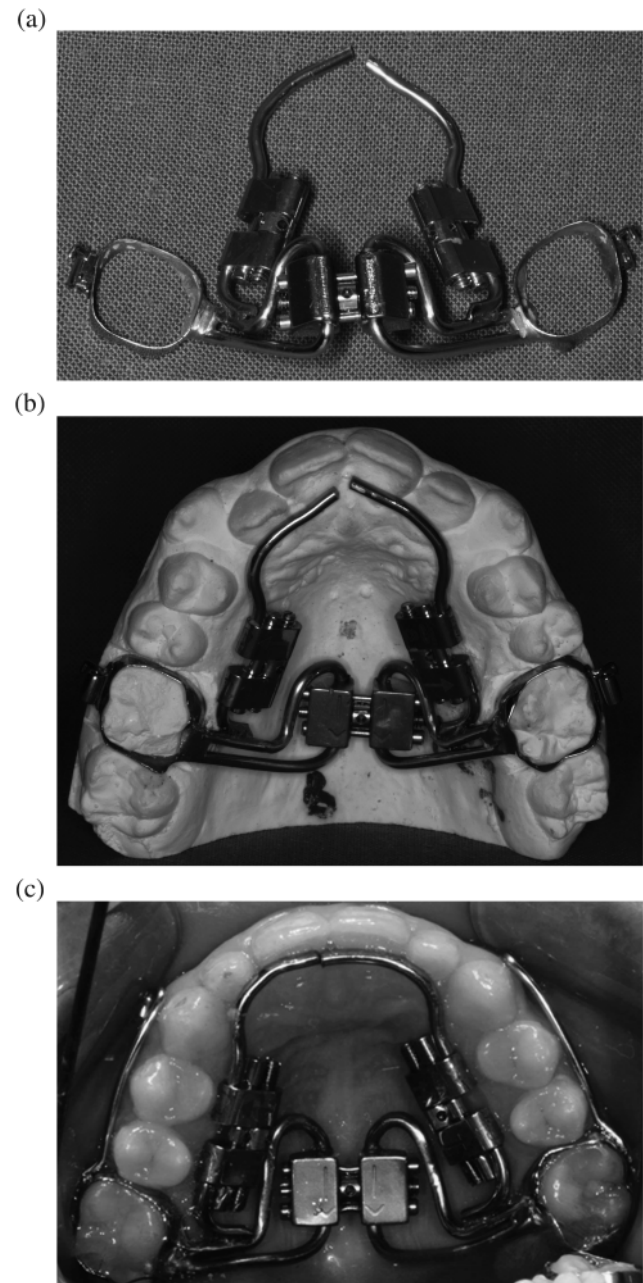


Figure 1 (a), (b), and (c) Transverse sagittal maxillary expander with two 0.045-inch stainless steel wires extended to the palatal surfaces of the central incisors and two 8 mm Hyrax-type screws attached to these wires between the molar bands and incisors.

Subjects and methods

The sample included 50 patients (24 females, 26 males), ranging in age from 6 to 15 years with a maxillary crossbite caused by narrowness of the apical base treated at the Department of Orthodontics, University of Milan.

All patients were selected based on the following criteria: no history of orthodontic treatment, primary dentition or early to mid mixed dentition, active growth, no craniofacial anomalies or syndromes, and the presence of a unilateral or bilateral posterior crossbite associated with maxillary hypoplasia.

Two treatment groups each containing 25 patients (13 males and 12 females) were constructed. The first group was treated with a TSME, a modification of the Hyrax RME, to correct the transverse and sagittal dimensions (Farronato *et al.*, 2007; Figure 1b and 1c). Fifty per cent of the subjects had a Class II malocclusion and the remaining 50 per cent a Class III malocclusion.

The TSME is a fixed device designed to develop archform in patients with constricted dental arches. It is specifically designed for transverse and antero-posterior arch development. The TSME consists of two bands cemented to the right and left first maxillary molars, a Hyrax-type transverse expansion screw, two 0.045-inch stainless steel wires extending to the palatal surfaces of the central incisors, and two 8-mm Hyrax-type screws attached to these wires between the molar bands and the incisors. The appliance may also be worn in association with extraoral devices.

The appliance was worn from 6 to 12 months. In the first phase, activation of the transverse screw consisted of a one-quarter turn twice per day for 15 days. In the second phase, the sagittal screws were activated one-quarter turn every 7 days for 6–8 months. The appliance was the left *in situ* for 4 months as passive retention.

The second group was treated using a Hyrax appliance. The Hyrax screw was activated twice per day with a one-quarter turn in the morning and in the evening for 15 days. The appliance was then left in place passive for 6 months. The subjects were observed weekly until over correction was obtained.

The material for this study consisted of the pre-treatment (T0) and post-retention (T1) lateral cephalograms.

Cephalometric analyses were performed. All measurements were recorded by the same operator (LG) independently on two separate occasions with a 1 week interval. For all cephalometric variables, differences between the independent repeated measurements and the mean T0 and T1 measurements were used, and treatment changes were calculated. No other treatment took place during the period from T0 to T1.

The cephalometric measurements analysed are shown in Figure 2.

Changes in cephalometric values in the RME and TSME groups during the observation period were calculated and compared.

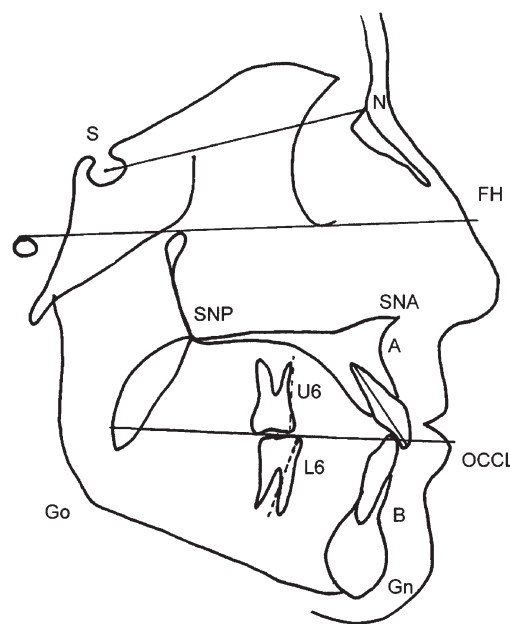


Figure 2 Cephalometric landmarks analysed in the study. SNA angle, SNB angle, ANB angle, SNP.A, SN–GoGn, SNP.SNA–Go.Gn, SN–SNP, SNA, S–Go, N–Me, ISN, IFH, U6–PP, L6–MP, and SN–occlusal plane.

Descriptive statistics included the means and standard deviations. The mean differences in cephalometric measurements at T0 and T1 were examined.

Statistical analysis was undertaken using a *t*-test for paired samples. $P < 0.05$ was considered significant (Table 1).

Results

Changes in the TSME group

SNA, SNB, and ANB angles showed a non-significant increase during treatment. In the Class II patients, this was a result of anterior repositioning of the mandible as a consequence of widening of the maxilla.

No statistically significant changes were observed in the vertical dimensions as the maxillary, occlusal, and mandibular planes were stable at T1. SN–GoGn increased in most patients, but these changes were not significant.

SN–SNP.SNA showed a non-significant rotation, and S–Go and N–Me also showed a non-significant modification during treatment.

The linear measurement, SNP–A, showed a significant increase indicating that the dentoalveolar maxillary process moved anteriorly because of the force delivered by the sagittal screws during active growth.

A statistically significant increase in ISN and IFH angles was also observed ($P < 0.05$). This was due to activation of the lateral screws that contributed to forward movement of the dentoalveolar process and labial movement of the incisors. No statistically significant

Table 1 Cephalometric measurements in patients treated with either a rapid maxillary expander (RME) or a transversal sagittal maxillary expander (TSME) at the start of treatment (T0) and at the end of retention (T1).

Variables	RME					TSME				
	TO		T1			TO		T1		
	Average	SD	Average	SD		Average	SD	Average	SD	
SNA (°)	79.2	2.97	80.6	2.98	NS	79.4	3	80.8	3	NS
SNB (°)	77.59	2.05	78.3	2.93	NS	77.21	3.6	78.19	3.6	NS
ANB (°)	1.61	2.68	2.3	2.76	NS	2.19	2.1	2.61	2	NS
SN.GoGn (°)	37.5	1	38.45	2.99	NS	33	0.58	34.6	1.6	NS
SNPSNA.GoGn (°)	27.1	1.5	27.9	3.09	NS	28.2	1.52	28	3.2	NS
SN.SNPSNA (°)	9.1	2.1	11.3	2.5	*	10.8	0.75	11.5	0.9	NS
S.Go (mm)	66.55	3.2	66.65	3.1	NS	67.3	2.5	67.9	2	NS
N.Me (mm)	107.6	3	110.15	3.02	*	104.3	2	104	3.2	NS
SN.PA (mm)	45.6	3.1	45.9	2.01	NS	45	4.1	48.6	2.05	*
ISN (°)	98.03	1.54	98.15	2	NS	101.65	6.3	109.9	5.2	*
IFH (°)	111.2	2.02	111.3	3.04	NS	110.46	6.2	119.3	4.2	*
U6.PP (mm)	18.6	2.01	19.4	2.1	*	21.5	2.1	23.7	3.6	NS
L6.MP (mm)	26.18	1.2	26.48	2.1	NS	29.6	0.075	29.7	0.9	NS
SN.OCCL (°)	25.2	1.19	26.1	2.2	NS	26.15	2.31	26.9	2.73	NS

NS, non-significant. * $P < 0.05$.

modifications of the dental molar measurements, U6.PP and L6.MP, were noted.

Overjet changed from negative to positive in all Class III patients. This was accompanied by forward movement of the dentoalveolar maxillary process.

Changes in the RME group

In the RME group, there were no significant alterations in the sagittal position of the maxilla. SNP-A showed a non-significant modification. SN-SNP.SNA displayed a downward and backward rotation. A significant increase ($P < 0.05$) of the dental molar measurement, U6.PP, was also noted. ISN and IFH did not show relevant modifications.

A statistical increase ($P < 0.05$) in total anterior face height (N-Me) was observed.

Comparison between the groups

During treatment, the increase in SNP-A, ISN, and IFH in the TSME group was significantly greater than in the RME group. The non-significant modification ($P > 0.05$) in the anterior vertical dimension (N-Me) in the TSME group showed a difference compared with the increase in the RME group.

Discussion

Expansion is indicated in subjects with maxillary hypoplasia and it is generally used to increase arch length. Sagittal arch

development is indicated when the archform is constricted since it helps resolve anterior crowding and proclination of the incisors and reduces the overbite. Labial movement of the anterior teeth may be combined with transverse development of the buccal segments where indicated (Clark, 2005).

In this study, in the RME group, no statistically significant alteration was found in the sagittal position of the maxilla, in agreement with Byrum (1971), Sarver and Johnston (1989), Da Silva *et al.* (1991), and Cozza *et al.* (2001). An increase in total anterior height was also noted as a direct effect of the vertical displacement of the maxilla and the upper molars, in agreement with Haas (1961, 1965, 1970), Davis and Kronman (1969), Wertz (1970), Wertz and Dreskin (1977), Da Silva *et al.* (1991), Akkaya *et al.* (1999), and Cozza *et al.* (2001).

The TSME is specifically designed for antero-posterior and transverse development. In this study, the TSME has a sagittal effect on the maxillary alveolar process. Significant alterations were found in the antero-posterior position of the maxillary alveolar process. This change occurred as a result of opening of the mid-palatal suture, bending and movement of the alveolar process anteriorly, and tipping of the incisors.

These results are in agreement with the findings of Kambara (1977) who, using study casts, cephalometric radiographs, and bone markers, found that the maxillary complex can be displaced anteriorly with significant changes in the circum-maxillary sutures, by stretching of sutural connective tissue fibres, new bone deposition along the

stretched fibres, and homeostasis that maintains sutural width. This result is positive both in Class II and III patients because mandibular growth is not restricted.

Dellinger (1973), Haas (1980), and Bishara and Staley (1987) also stated that the advantages of RME were a rotational relocation of the mandible that provides vertical clearance for simultaneous reduction of an anterior crossbite and/or protraction of the maxillary complex. Early treatment with the TSME shows promising results.

Cozza *et al.* (2001) recommended different types of maxillary expansion appliances by changing the rate of expansion and form of the appliance. The TSME increases the perimeter length of the upper arch in subjects with maxillary hypoplasia. It is easy to use, with placement and activation procedures similar to those of a traditional RME. Patient comfort is satisfactory and compliance is not an issue because the appliance is fixed.

Conclusions

The findings of this study show that the TSME can produce skeletal changes due to the transverse force and dentoalveolar modification to the sagittal component that can increase available arch length resulting in the correction of maxillary hypoplasia.

The non-significant increase in the anterior vertical dimension observed indicates that the TSME may be advantageous in patients with an anterior open bite.

References

- Akkaya S, Lorenzon S, Ucem T T 1999 A comparison of sagittal and vertical effects between bonded rapid and slow maxillary expansion procedures. *European Journal of Orthodontics* 21: 175–180
- Asanza S, Cisneros G J, Nieberg L G 1997 Comparison of Hyrax and bonded expansion appliances. *Angle Orthodontist* 67: 15–22
- Bishara S E, Staley R N 1987 Maxillary expansion: clinical implications. *American Journal of Orthodontics and Dentofacial Orthopedics* 91: 3–14
- Byrum A G 1971 Evaluation of anterior-posterior and vertical skeletal changes in rapid palatal expansion cases as studied by lateral cephalograms. *American Journal of Orthodontics* 60: 419–425
- Clark W J 2005 Transforce lingual appliances for arch development. *Journal of Clinical Orthodontics* 39: 137–142
- Cleall C F 1974 Dentofacial orthopedics. *American Journal of Orthodontics* 66: 237–250
- Cozza P, Giancotti A, Petrosino A 2001 Rapid palatal expansion in mixed dentition using a modified expander: a cephalometric investigation. *Journal of Orthodontics* 28: 129–134
- Da Silva O G, Villas Boas M C, Capelozza L 1991 Rapid maxillary expansion in the primary and mixed dentitions: a cephalometric evaluation. *American Journal of Orthodontics and Dentofacial Orthopedics* 100: 171–181
- Davis M W, Kronman J H 1969 Anatomical changes induced by splitting of the midpalatal suture. *Angle Orthodontist* 39: 126–132
- Dellinger E L 1973 A preliminary study of anterior maxillary displacement. *American Journal of Orthodontics* 63: 509–516
- Farronato G P, Loiaconi G, Salvato A, Bruno E 1982 Disgiunzione rapida del palato: I parte: basi biologiche. *Mondo Ortodontico* 4: 1–10
- Farronato G P, Loiaconi G, Salvato A 1983 Disgiunzione rapida del palato. II parte: risultati clinici. *Mondo Ortodontico* 6: 49–56
- Farronato G *et al.* 2003 Attuali orientamenti in ortognatodonzia. Parte prima. *Il dentista Moderno* 9: 23–43
- Farronato G, Cordasco G, Farronato D, Esposito L, Briguglio E 2007 The transverse sagittal maxillary expander. *Journal of Clinical Orthodontics* 41: 387–389
- Haas A J 1961 Rapid expansion of the maxillary dental arch and nasal cavity by opening the midpalatal suture. *Angle Orthodontist* 31: 73–90
- Haas A J 1965 The treatment of maxillary deficiency by opening the midpalatal suture. *Angle Orthodontist* 35: 200–217
- Haas A J 1970 Palatal expansion: just the beginning of dentofacial orthopaedics. *American Journal of Orthodontics* 57: 219–255
- Haas A J 1980 Long-term post-treatment evaluation of rapid palatal expansion. *Angle Orthodontist* 50: 189–217
- Harvold E P, Chierici G, Vargervik K 1972 Experiments on the development of dental malocclusions. *American Journal of Orthodontics* 61: 38–44
- Kambara T 1977 Dentofacial changes produced by extraoral forward force in the *Macaca irus*. *American Journal of Orthodontics* 71: 249–277
- Linder-Aronson S, Lindgren J 1979 The skeletal and dental effects of rapid maxillary expansion. *British Journal of Orthodontics* 6: 25–29
- McNamara J A Jr, Brudon W L 1993 Orthodontic and orthopedic treatment in the mixed dentition. Needham Press, Ann Arbor
- Sarver D M, Johnston M W 1989 Skeletal changes in vertical and anterior displacement of the maxilla with bonded rapid palatal expansion appliances. *American Journal of Orthodontics and Dentofacial Orthopedics* 95: 462–466
- Timms D J 1976 Long term. follow-up of cases treated by rapid maxillary expansion. *Transactions of the European Orthodontic Society* pp. 211–215
- Wertz R A 1970 Skeletal and dental changes accompanying rapid midpalatal suture opening. *American Journal of Orthodontics* 58: 411–466
- Wertz R A, Dreskin M 1977 Midpalatal suture opening: a normative study. *American Journal of Orthodontics* 71: 367–381